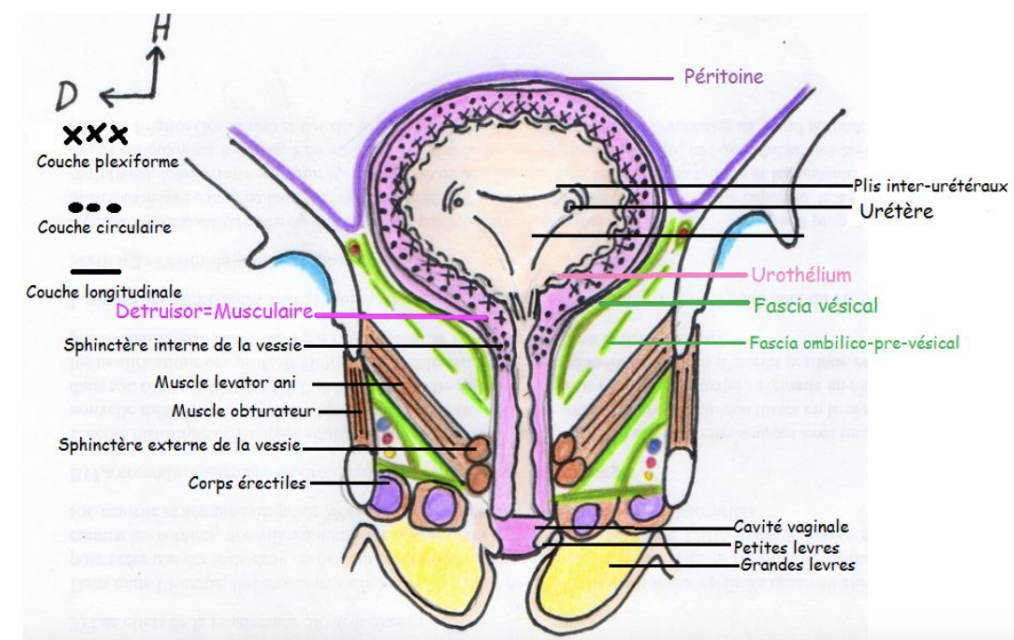
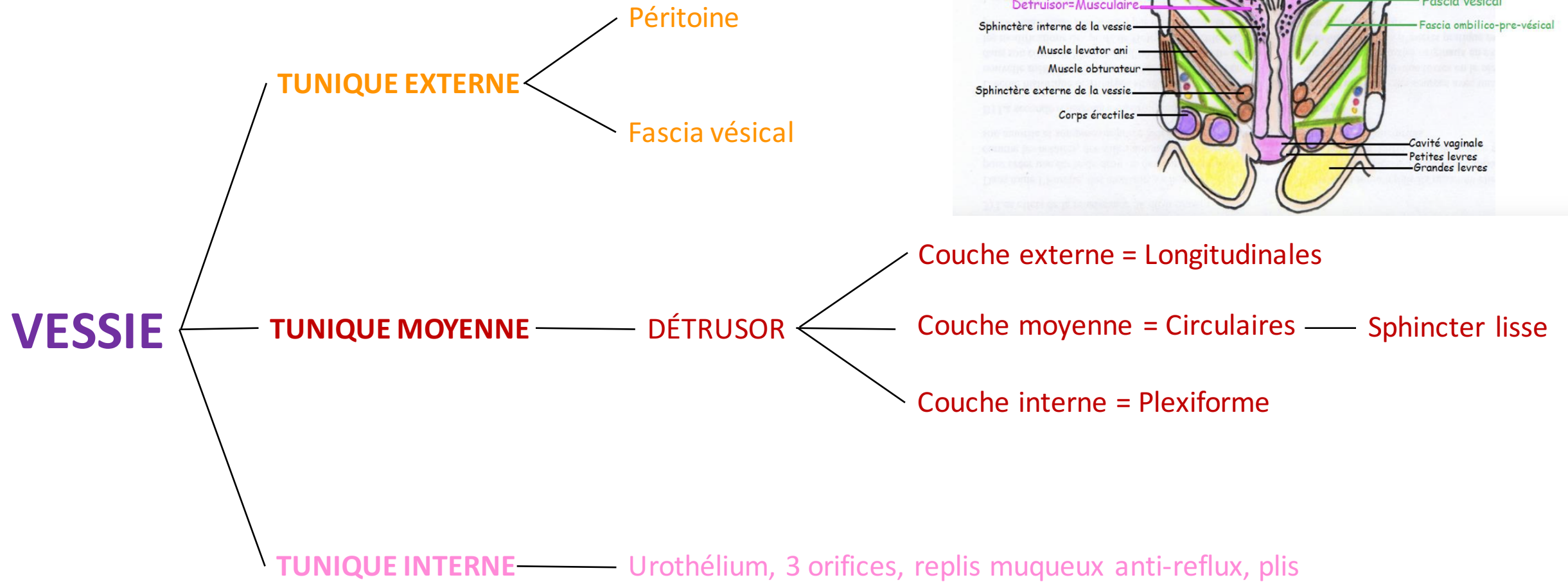


Sous-péritonéal / Partiellement péritonisée / rétro-pubienne si vide



*Artère ombilicale ++